

Large Volume Fat Graft for Breast Augmentation

AMR ABD EL MONIEM EL-NAGGARY, M.D.* and HOSSAM EL DIN TAHSEEN, M.D.**

The Department of General Surgery, Faculties of Medicine, Fayoum and Cairo** Universities*

ABSTRACT

After numerous experiments with free-fat transfer since 1893 [1], many promising methods and results of large-volume fat grafts have been published recently [2]. A common disadvantage was the time of the procedure and a lack of proof of efficiency. In 2007 BEAULI™ method was developed with the (Berlin autologous lipotransplantation) a new and reliable procedure to collect larger amounts of transplantable fatty tissue. It was evaluated in a prospective clinical study with 85 patients in 2 centers in Germany, the overall number of transplantations amounting to 216 treated breasts. Indications were general lack of breast volume, either genuine or acquired in the course of surgical procedures. The fat was harvested with the BEAULI™ method, which consists in general of the harvest of very small fat particles by means of water-assisted liposuction (body-jet®, human med AG, Germany) and reinjection of the fat after separation from superfluous water by means of the LipoCollector®.

All procedures were performed in a standardized pattern, measurements were taken preoperatively, at day 1 postoperative, after 1 week, 4 weeks, 3 months, 6 months and then to be continued yearly. An MRI of the breasts was taken preop and 6 months postoperatively, the longest follow-up is 30 months. Operation time was (on average) 1.5h. In every case a definite increase of the volume of the fatty layer in the treated areas was observed. After implant removal, satisfaction was usually reached after only a single procedure, for complete reconstruction after cancer surgery 4-5 grafting sessions were necessary. An extension of the skin envelope as well as improvement of existing scars were observed.

INTRODUCTION

100 years have elapsed since the first published description of an adipose tissue transplantation by Nueber [1] and of partial breast reconstruction through injection of autologous adipose tissue by Holländer [2]. Following a series of publications during the pre-world II period the topic receded almost to being forgotten. An outstanding exception in the subsequent years is the study by Peer [3]. Only after liposuction was introduced by Fischer and in particular by Illouz [4] did adipose tissue transplantation come into vogue [5]. However, in 1987 an ASRPS "Ad Hoc Committee on New Procedure" rejected fat transplantation in the breast

without a basis of evidence. This position has only recently been revised [6]. There was a strong upswing in a scientific investigation of the subject with the publication of research by von Chajchir [7], Coleman [8], Delay [9], Riggotti [10]. More recently numerous groups of researchers in different countries have experimented with autologous fat transplantation in the breast. In Germany, one of such groups is the DGPRAC [11]. All previous methods have encountered a severe limitation – the duration of the operation itself. The original technique (LipoStructure) used by Coleman in aesthetic bilateral breast enlargement took at least 5-7h. Other approaches are associated with rather high costs (BRAVA), have sometimes had only a low rate of fat integration, or provide no real proof of an effective integration rate. Another currently discussed question is supplement tissue grafting with fat stem cells (ADSC) [12]. These cells are isolated from the adipose tissue through greater angiogenesis. However, this hypothesis still lacks evidence-based proof. Furthermore, the duration of the fat cell transplantation procedure is considerably lengthened (by at least 2h) and costs are significantly raised. Its wide clinical use does not currently seem to be feasible.

Whenever a rather large portion of the transplanted fat is discarded because of poor perfusion (tissue clumping), it should be noted that not all the necrotic cells are carried off by macrophages, but undergo a confluence into oil cysts through the lack of contact with well perfused tissue following autolysis of the cell membrane, and then can become calcified, as several publications have described [13].

Aim of the work:

The objective of this research therefore was to measure the efficacy of a technique for cell-friendly harvesting of fat cell particles which would considerably reduce operation time and concomitantly

result in a high integration rate among the transplanted fat cells.

Since 2009 I have been conducting water jet assisted liposuction (WAL) and made the harvested fat available for fat cell research.

MATERIAL AND METHODS

10 Non-smoking patients with a BMI between 20 and 30 were included. All patients desired improvement in breast size and at the same time refused to undergo a conventional breast augmentation procedure. They received a detailed explanation of the possible risk of formation of oil cysts and calcification.

First, all patients were measured for height, weight, breast meridian and maximum circumference of each breast, measured from the medial to the lateral attachment; standardized photo documentation (mirror image) was added.

Data on the areas suctioned, the amount of a graft used, distribution subcutaneously or in the pectoral muscle, and the results of centrifugation were recorded.

The postoperative data (height, weight, measurements, maximum circumference of each breast, measured from the level of the anterior axillary line over the mamilla to the medial attachment) were recorded on the day following the operation, after 1 week, 1 month, 3 months, and 6 months.

Liposuction was performed on the day of the operation, preferably from areas of the abdomen and the flanks and on the outside and inside of the thighs. The area for harvesting was selected according to the wishes of the patient. The area to be suctioned was first infiltrated with the body-jet® using a Klein standard tumescence solution (composition: 500mg lidocaine, 1mg adrenaline and 12.5ml sodium bicarbonate 8.4% in a 1l solution) [14] and liposuction was started without a waiting period. Infiltration and liposuction were performed with the same solution. The liposuction procedure involved the application of a pulsing water jet on the body-jet® device-with the setting at level-and constant irrigation with tumescence solution and negative pressure, which was limited to -0.5 bar. The cannula used was the 3.8m body-jet® Rapid cannula with effective suction apertures of 0.9mm. These narrow apertures enable harvesting of equally small fat cell structures which also integrate well.

The same step included the separation of the fat in the LipoCollector™ from the aqueous ele-

ments so that the amount of residual fluid in the mixture was equivalent to that after 10min decanting.

The LipoCollector™ (Fig. 1a,b) basically consists of a prefilter to remove fibrous elements which could choke the thin injection cannulas. The fat flushed out by continual irrigation is separated from the excess fluid by means of a sieve in the LipoCollector.

The fluid is then suctioned off and the separated washed fat remains sterile on the operating table for later use.

An average of 60min. was needed (including prefiltration) to harvest 600ml of transplantable clear adipose tissue.

The harvested fat was then suctioned from the container with the BEAULITM extraction cannula and 50cm³ syringes. These are left upright for 10min in a stand on the table and fluid settling at the base is removed in 10cm³ syringes (Fig. 2) utilities BEAULI injection cannulas. Re-injection is made via small, approx. 5cm, laterocaudal stab incision of the breast. All segments of the breast are accessible from the incision because of the length of the cannula. Fat infiltration is performed exclusively in the area of subcutaneous adipose tissue and the pectoral muscle. The adipose tissue is usually distributed so that about two-thirds is placed in the area of subcutaneous fat and about one-third intrapectorally. The pectoral muscle was probed by palpating bluntly against the nearest rib with the cannula and then performing the injection directly above the ribs while maintaining constant contact with them. Care was taken during distribution of the fat to ensure that the tissue was not subjected to excessive tension, to avoid application of additional pressure around the fat cells. A cotton pad was applied for 2 days to avoid pressure on the breast and to cool the tissue. A compression brace was placed on the graft harvesting areas. Wearing of a compression bra and avoidance of physical exertion were not necessary.

RESULTS

Between 1 October, 2009 and 31 January, 2012 a total of 10 patients were treated with autologous fat grafts for breast augmentation with this method. The indications were a desire for aesthetic enlargement, reconstruction after partial or total mastectomy, or capsular fibrosis after silicone implants in combination with refusal of implants.

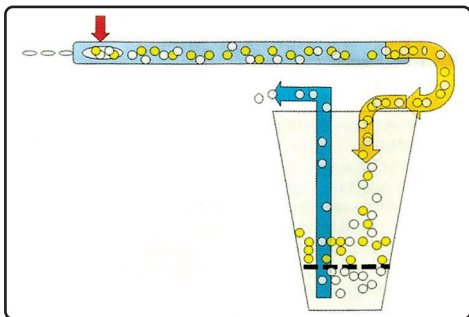


Fig. (1-A): LipoCollector (diagram).



Fig. (1-B): The lipocollector.

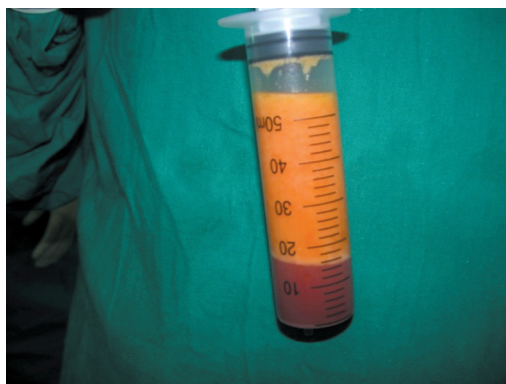

Fig. (2): 50ml syringes for fat collection.

6 patients who had undergone aesthetic augmentation were evaluated for volume since they presented too many individual factors after implant removal or reconstruction.

Analysis of the clinical follow-up record gave the following results: Mean operation time (incision-to-suturing): 92min with a significantly declining trend. Currently, the operation time stands at approximately 1h.

The development of breast circumference over an assessment period of 6 months appears that measurement of the particular circumference of each breast from the anterior axillary line to the medial attachment over the largest circumference does not in fact represent an exact measuring criterion, but overall it gives a good indicator of the resorption behaviour of the fat. Similar development

can be seen in the breast meridian. The measurements correlate with the clinical observation that no further volume loss occurs after postoperative month 3. Significant haematoma formation in the breasts area was not found. Pain was predominantly localised to the graft harvesting area.

DISCUSSION

The body-jet (Fig. 3) method for liposuction meets four important criteria first, it is a body friendly procedure, second it has a low level liposuction and it allows good perfusion of small particles adipose tissue. At the same time it does it in a relatively small amount of time, 4th and most important that it allows breast augmentation without any scars.

Post operative results were satisfactory to the patient and the breast measurements taken after 6 months were almost the same as the measurements taken shortly post operative. Usually the maximum size is reached 1 week after the operation due to the tissue oedema.

The oedema subsides after 4 weeks and no further decrease in size after 3 months.

Regarding the complications were minor complications including haematoma and subcutaneous granulomas.

The post operative stress post operative was almost nil that is why 80 percent of the patients decided to have fat injection again.

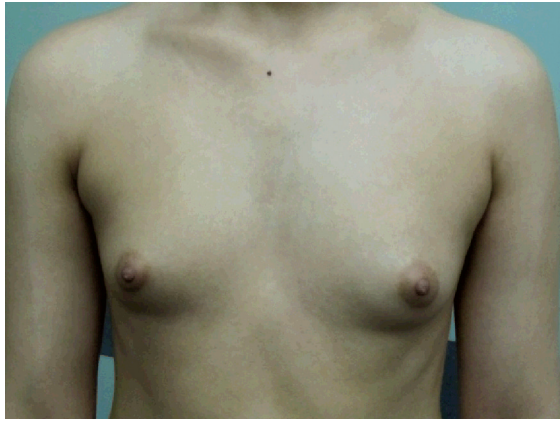
Usually the patient needs 2 interventions and in few cases 3 interventions are needed but some cases did not need any further more interventions (case 3).

In the second intervention it is easier to inject more volume of fat due to now-existing expansion of the receiving site.

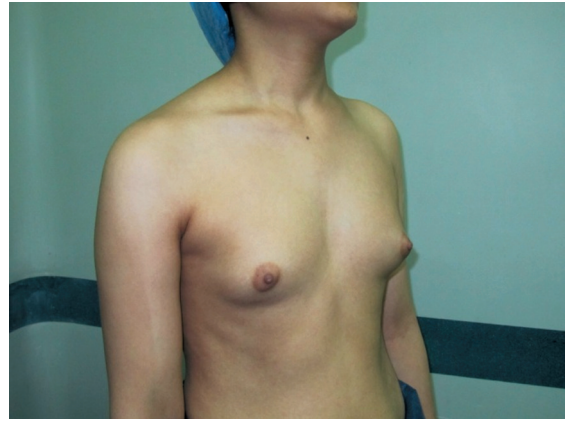


Fig. (3): The body-jet.

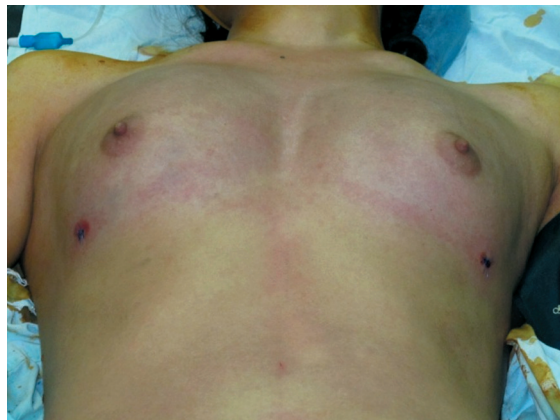Case (1):



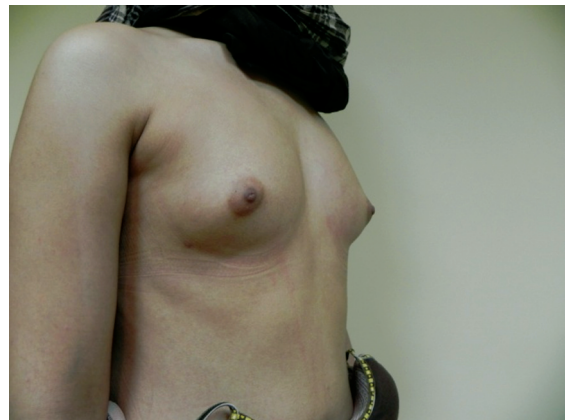Case (1A): Pre operative anterior view.



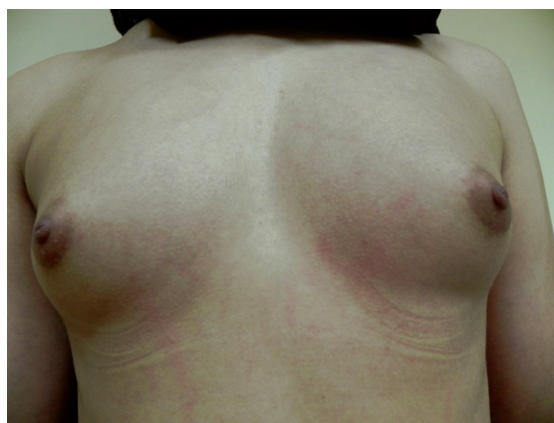Case (1B): Pre operative photo oblique view.



Case (1C): Intra operative photo.

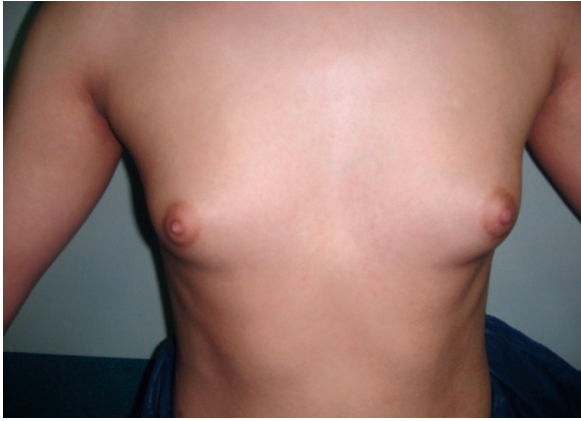


Case (1D): Post operative oblique view.

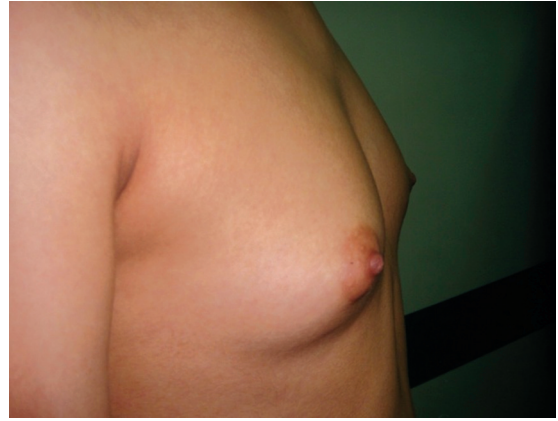

Case (1E): Post operative anterior view.

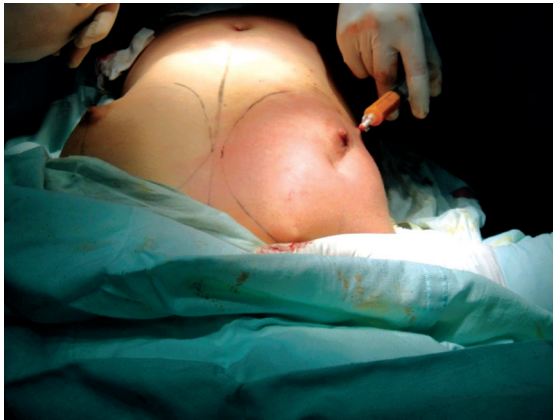Case (2):



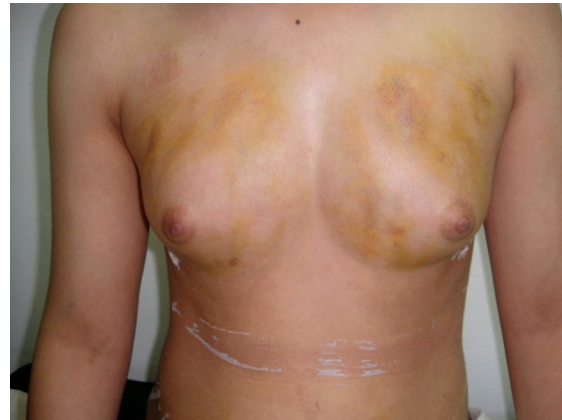Case (2A): Pre operative anterior view.



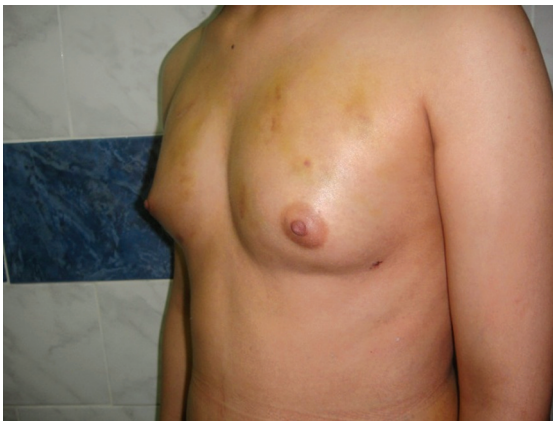Case (2B): Pre operative photo oblique view.



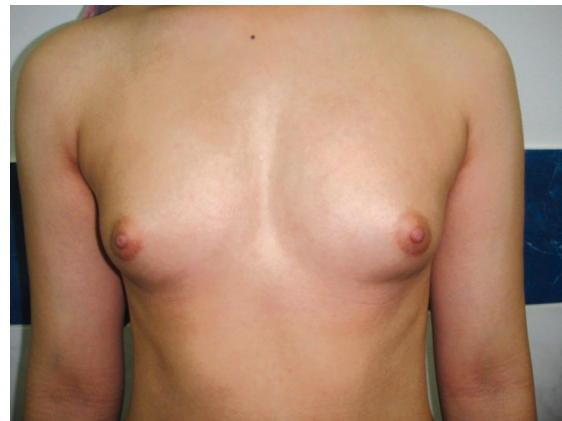Case (2C): Intra operative photo.



Case (2D): 1 week post operative anterior view.

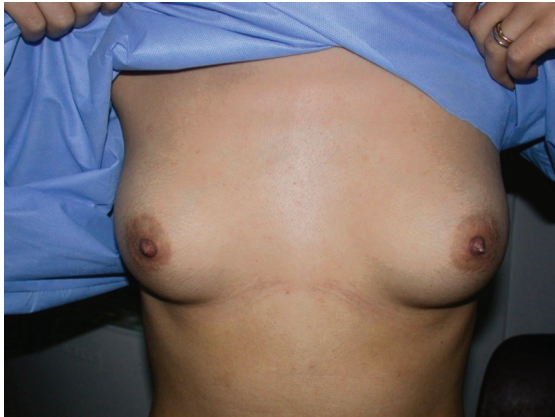

Case (2E): 1 week post operative oblique view.

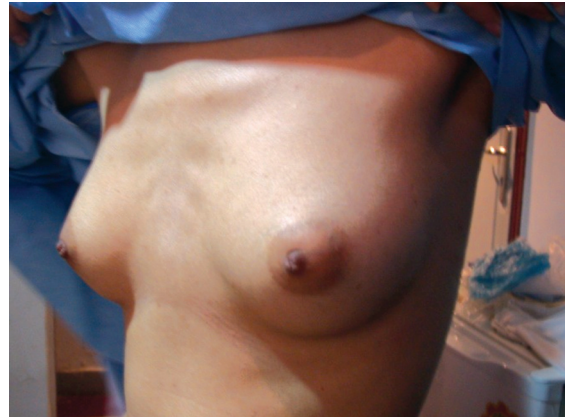

Case (2F): 3 months post operative.

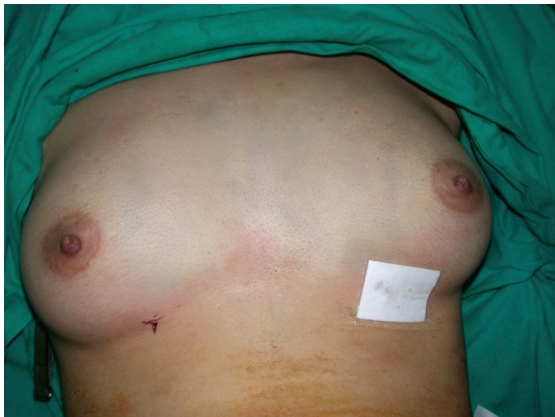Case (3):



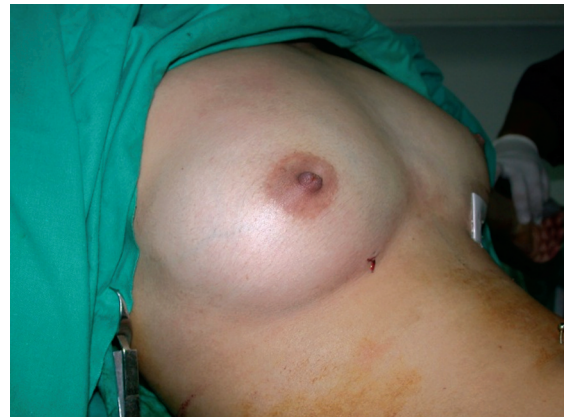Case (3A): Preoperative anterior view.



Case (3B): Preoperative oblique view.



Case (3C): Intraoperative anterior view.



Case (3D): Intraoperative lateral view.



Case (3E): 6 months post operative anterior view.



Case (3F): 6 months post operative oblique view.

Conclusions:

The body-jet is proved to be a safe method for fat injection for breast augmentation with good results and few complications consuming less time than other methods.

REFERENCES

- 1- Neuber G.: Über die Wiederanheilung vollständig vom körper getrennter, die ganze Fettschicht enthaltender Hautstücke. In: Zbl f Chirurgie, 30: 16, 1893.
- 2- Hollander E.: Über einen fall von fortschreitendem Schwaund des Fettgewebes und seinen kosmetischen Ersatz durch menschenfett. In: Munch Med. Wochenschr, 57: 1794-1795, 1910.
- 3- Peer L.: Loos of weight and volume in human fat graft, with postulation of a "cell survival theory". In: Plast Reconstr. Surg., 5: 217-230, 1950.
- 4- Illouz Y.G.: Body contouring by lipolysis: A 5-year experience with over 3000 cases. Plast. Reconstr. Surg., 72: 591-597, 1983.

- 5- Bircoll M.: Autologous fat transplantation to the breast. *Plast. Reconstr. Surg.*, 82: 361-362, 1988.
- 6- Gutowski K.A.: Current applications and safety of autologous fat grafts: A report of the ASPS fat graft task force. *Plast. Reconstr. Surg.*, 124: 272-280, 2009.
- 7- Chajchir A. and Benzaque I.: Fat-grafting injection for soft-tissue augmentation. *Plast. Reconstr. Surg.*, 84: 921-934, 1989; discussion 935.
- 8- Coleman S.R. and Saboeiro A.P.: Fat grafting to the breast revisited: safety and efficacy. *Plast. Reconstr. Surg.*, 119: 775-785, 2007; discussion 777-786.
- 9- Delay E., Garson S., Tousson G., et al.: Fat injection to the breast: Technique, results, and indications based on 880 procedures over 10 years. *Aesthet. Surg. J.*, 29: 360-376, 2009.
- 10- Rigotti G.: Lipoaspirated stem cells may not have been placed in ischemic tissue: Reply. *Plast. Reconstr. Surg.*, 122: 680-681, 2008.
- 11- Rennekampff H.O., Remers K., Gabka C.J., et al.: Möglichkeiten und Grenzen der autologen Fetttransplantation "Consensus Meeting" der DGPRAC in Hannover, September 2009. *Handchir Mikrochir Plast. Chir.*, 42: 137-142, 2010.
- 12- Brayfeild C., Marra K. and Rubin J.P.: Adipose stem cells for soft tissue regeneration. *Handchir Mikrochir Plast. Chir.*, 42: 137-142, 2010.
- 13- Pulagam S.R., Polouton T. and Mamounas E.P.: Long-term clinical and radiological results with autologous fat transplantation for breast augmentation: Case reports and review of the literature. *Breast J.*, 12: 63-65, 2006.
- 14- Klein J.A.: Anesthesia for liposuction in dermatologic surgery. *J. Dermatol. Surg. Oncol.*, 14: 1124-1132, 1988.